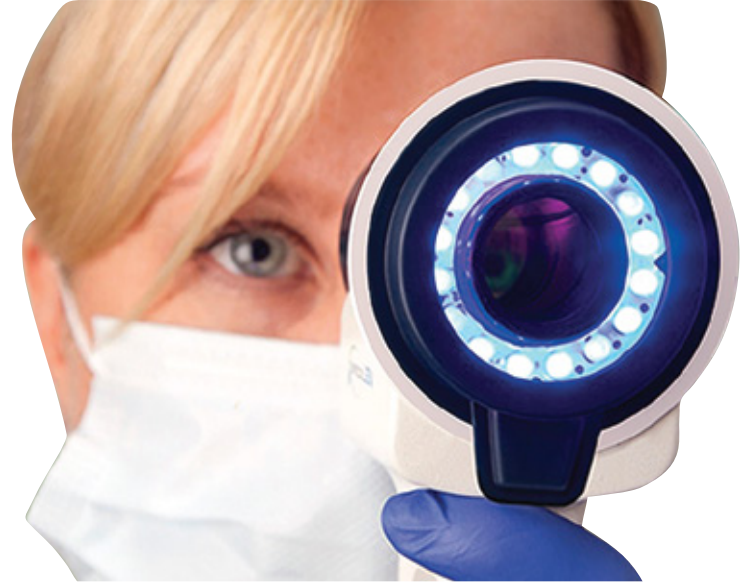



Better Surgery

VELscope Vx Guided Surgery & DNA Ploidy Testing is A Game Changer in Oral Cancer Treatment

Over 200,000 cases of Head and Neck Cancers occur each year in India. After treatment, more than 50 percent of severe cases patients will develop recurrence within two years of treatment^[1]. Loco-regional recurrence is the most common cause of high morbidity and mortality in head and neck cancer patients^[2, 3].

VELscope Vx guided surgery reduce 3-years local recurrence rate from 40.6% to 6.5%^[4]



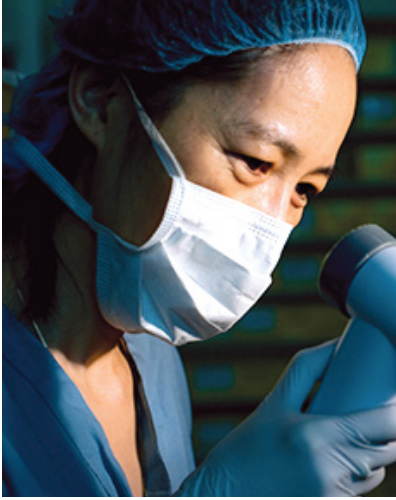BC Cancer Agency
CARE + RESEARCH



Recommended by
World Health
Organization



Oral Surgeons and the VELscope System: Partners in Early Detection, Diagnosis & Better Treatments



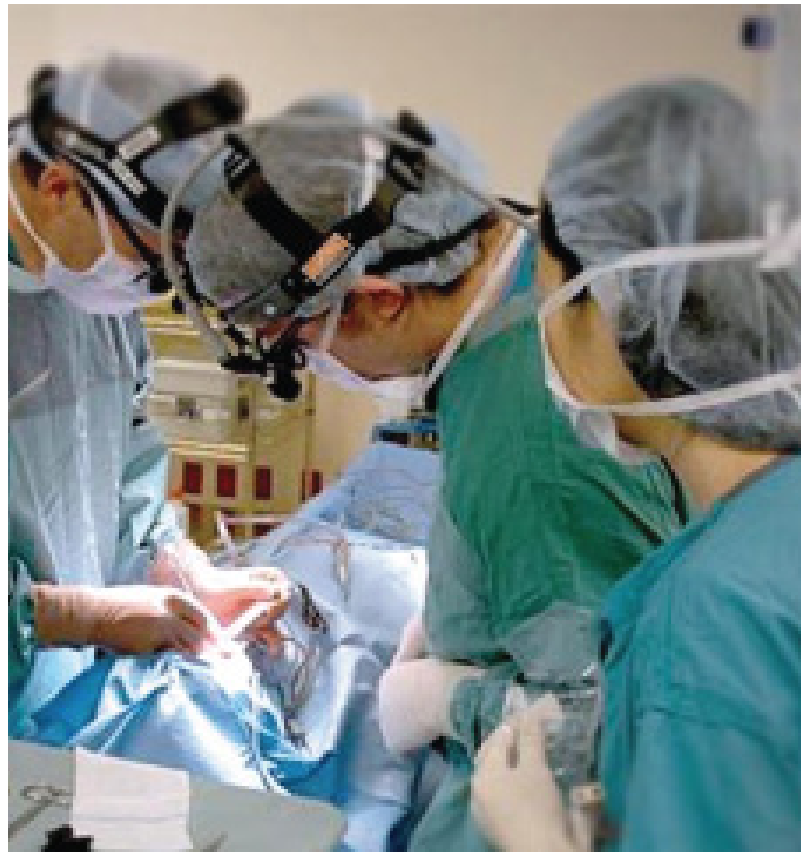
“Use of FV technology is currently not standard for all oral cancer surgeries to help surgeons decide how and where to remove diseased tissue, so this is a new way to perform oral cancer surgery and look at how this disease spreads.”

Prof. Dr. Catherine F. Poh, DDS, PhD, FRCD (C),
Clinician Scientist, Oral Pathologist and
Consulting Dentist, BC, Canada.

The use of fluorescence visualization (FV) during oral cancer surgery drastically improves the accuracy of the removal of cancerous tissue, significantly reducing local recurrence rates of oral cancer.

Currently, surgical removal of cancerous lesions in the mouth requires cutting an extra 10 mm around the lesion (or tumor) in the hopes of removing cancerous cells that are often spreading and hard-to-see to unaided eyes. However, the retrospective case-control observational study published in JAMA^[5] showed that even with the standard use of the additional 10 mm margin, one-in-three patients will still experience a local recurrence of cancer.

“With the use of FV technology, we hope to accurately remove all cancerous tissue and spare normal tissue in one surgery”



“With FV technology we found that the extension of this disease is not uniform around the cancerous area, so a 10-mm margin around the tumor site may not always work,” explains Dr. Poh, who is also an oral pathologist and associate professor in the Faculty of Dentistry at the University of British Columbia.

According to Dr. Poh, head and neck surgeons in B.C. have already changed their practice and standardized the use of VELscope Vx during oral cancer surgery.



“VELscope allows us to add new dimension to detect abnormalities which may be histologic or perhaps only genetic and use those in real time way to evaluate surgical margins”

Prof. J. Scott Durham, BSc MD FRCSC
Head, VGH Otolaryngology - Head and Neck Surgery



“We see recurrence rate decrease significantly in both, invasive cancers and cases of severe dysplasia, when surgical margins are determined using Tissue Fluorescence Visualization.”

Dr. Calum MacAulay PhD
Clinical Associate Professor, UBC
Head of Integrative Oncology Distinguished Scientist
Serves as Head, Cancer Imaging Department, B.C. Cancer Research Centre, BCAA



“I have got immense benefits and a lot of satisfaction using this equipment in my practice.”

Dr. Prakash Patil
BDS, MDS - Oral & Maxillofacial Surgeon
Face and Dental Hospital in Pune



"I am in a field of oral oncology, performing onco-surgeries for the last 10 years, I find VELscan very useful for doctors and patients in early detection of oral cancer and better treatment outcomes."

Dr. Vijaykumar Girhe

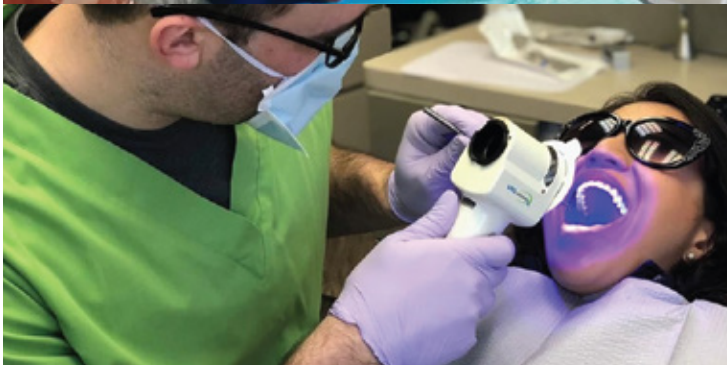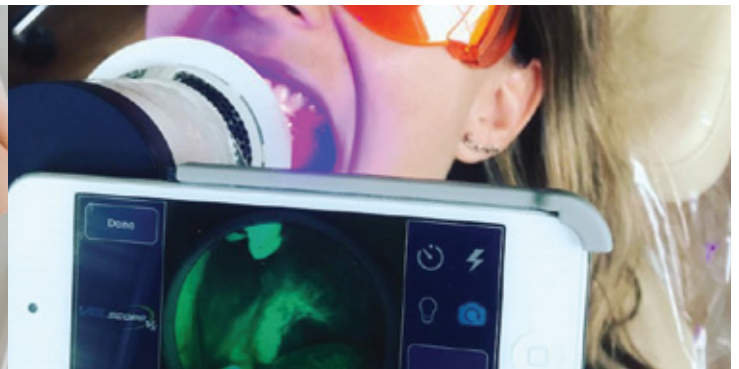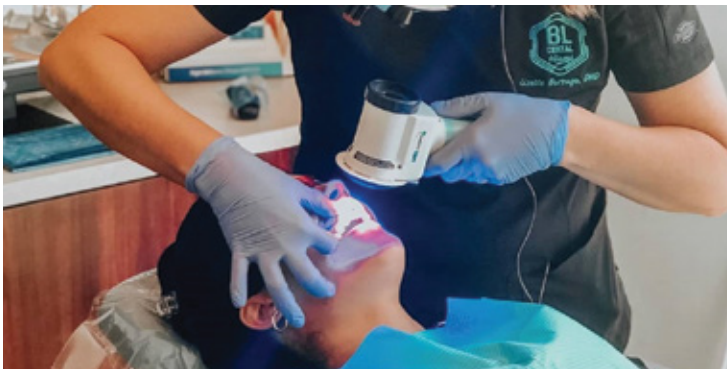
BDS, MDS - Cranio-Maxillofacial
Surgeon specializing in oncology
Dr. Girhe Dental Clinic, Aurangabad



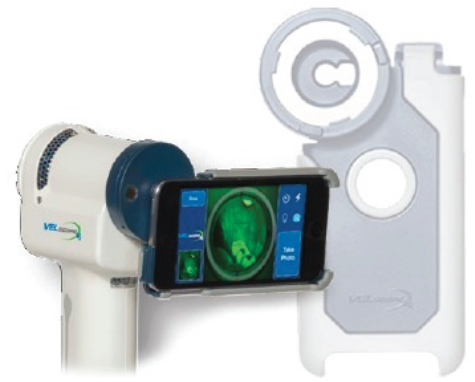Currently is using DNA Ploidy test and VELscope Vx to determine the appropriate surgical margin and biopsy site in his practice. As well as conducting research in the use of VELscope to assess cellular changes occurring in oral premalignancy.

Dr. Pushkar P Waknis

Professor & Consultant Maxillofacial Surgeon
MDS (Mumbai)
FIBOMS, MFDS RCPS (Glas) UK



What Does All This Mean for Oral Surgeons?



1. Early disease discovery
2. DNA Ploidy site/ Biopsy site guidance
3. Determination of appropriate surgical margins around lesions to help ensure that all diseased tissue is removed.
4. Better appreciation of the full scope of mucosal involvement of particular lesions.
5. Finding difficult to detect or clinically occult satellite lesions whether they be dysplastic or outright cancer.
6. Use of abnormal fluorescence patterns and loss of fluorescence as an aid to lesion risk assessment.
7. Photo Documentation to provide evidence-based care.



Provide evidence based care building patient trust



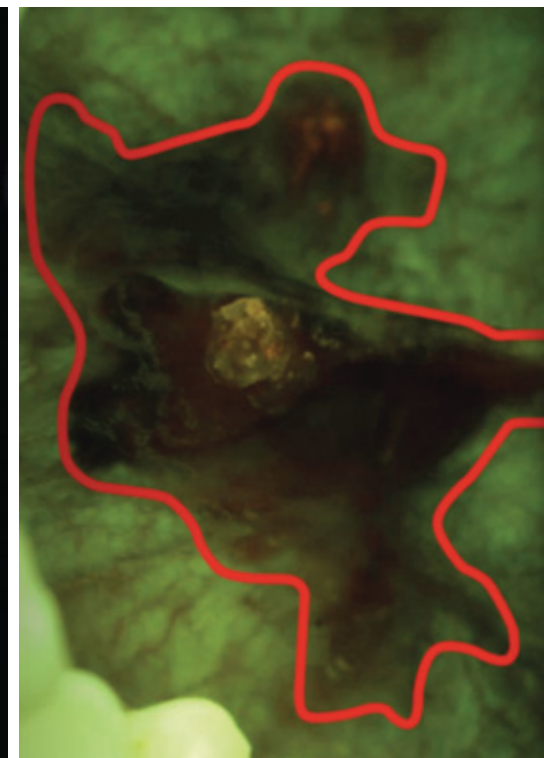
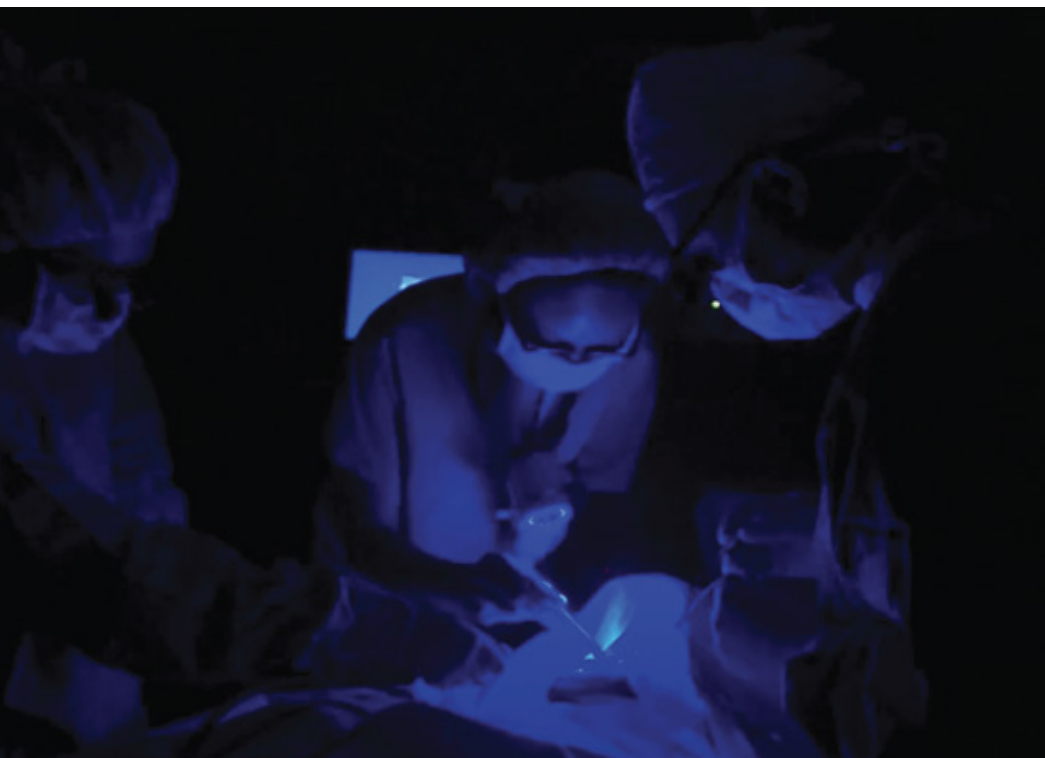Improved quality of patient care



Save Lives and earn respect in community



Grow practice with empowered team



Prevent Recurrence with DNA Ploidy Testing

Regular VELscan & DNA Ploidy Test for oral cancer survivors is crucial in order to prevent recurrence or detect it at very early stage.

Quantified DNA Ploidy Painless & Accurate Diagnosis on a Molecular Level

AI-Powered DNA Ploidy test, developed by British Columbia Cancer Research, is world's most advanced and accurate quantitative DNA Ploidy test which can detect aneuploidy in suspicious oral cells, **up to 2 years earlier than cytology or histology alone.**


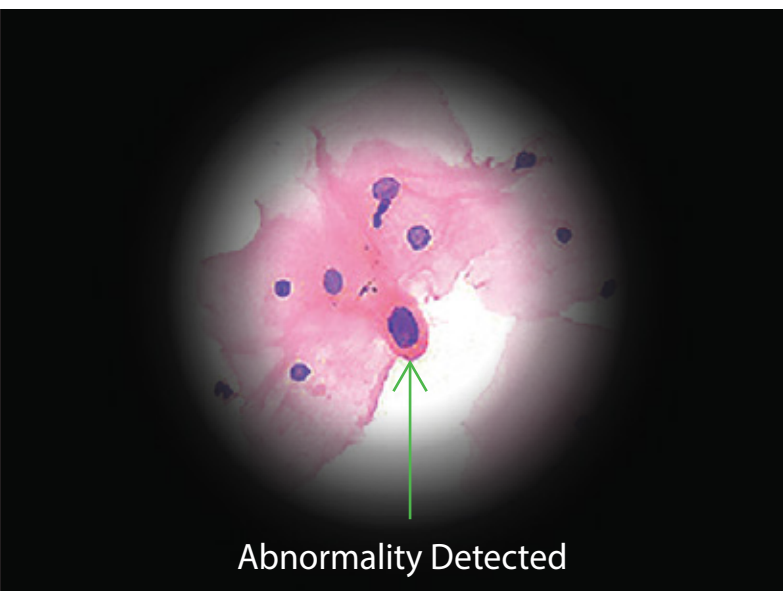
- Every cell counted; DNA index measured
- Objective results & Highest Accuracy
- Detects abnormal cells up to 2 years earlier
- Detection in pre-cancerous stage

DNAscan®
BEFORE SYMPTOMS



BC Cancer Agency
CARE + RESEARCH

- Monitors biological cell behaviour
- Non-invasive sample collection
- Sample multiple sites
- Automated report generation



VELscan & DNA Ploidy Testing Protocol

Pre-Surgery

DNA Ploidy test is done to identify if aneuploidy, which is proven biomarker for cancer, is present in suspicious oral tissue.

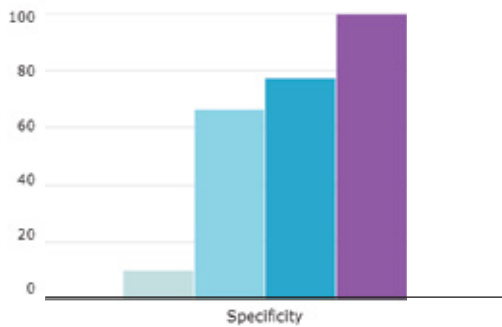
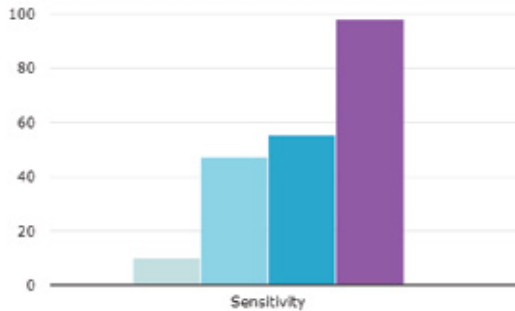
Post-Surgery

DNA Ploidy test is done to confirm there is no abnormal cells left in a surgical site, once surgical site is healed.

Routine Screening

Routine annual screening conducted to monitor biological cell behavior in order to prevent loco-regional recurrence or detect it very early.

Visual Inspection PAP Smear
Liquide Based Cytology DNA ICM



AI-Powered DNA Ploidy Test has the highest accuracy for a non-invasive diagnostics:

Sensitivity 98%

Specificity 100%

DNA DIAGNOSIS	RECOMMENDATION
No cells were detected with abnormal DNA amount	Routine screening is recommended
1-2 cells were detected with abnormal DNA amount (DI>2.5)	Repeated screening is recommended in 3 to 6 months
5%-10% of the cells are proliferating (going through the cell cycle, DI = 1.252.5)	Repeated screening is recommended in 3 to 6 months
3 or more cells were detected with abnormal DNA amount (DI>2.5)	Biopsy is recommended to confirm malignancy and determine the grade and stage of tumor.
Over 10% of the cells are proliferating (going through the cell cycle, DI = 1.252.5)	Biopsy is recommended to confirm malignancy and determine the grade and stage of tumor.
The sample is unsatisfactory	Repeated screening is recommended as soon as possible

Proven Benefits

Aneuploidy is a proven biomarker for cancer for more than 100 years.

- **Developed by British Columbia Cancer Research**
- **Internationally standardized by Consensus Reports of the European Society for Analytical Cellular Pathology (ESACP)**
- **Covered by National Health Insurance in Germany**
- **Successfully commercialized in China, Canada, Germany and now India**

Certified by:

Health Canada (Health Regulator)

Gemeinsamer Bundesausschuss (Health Regulator)

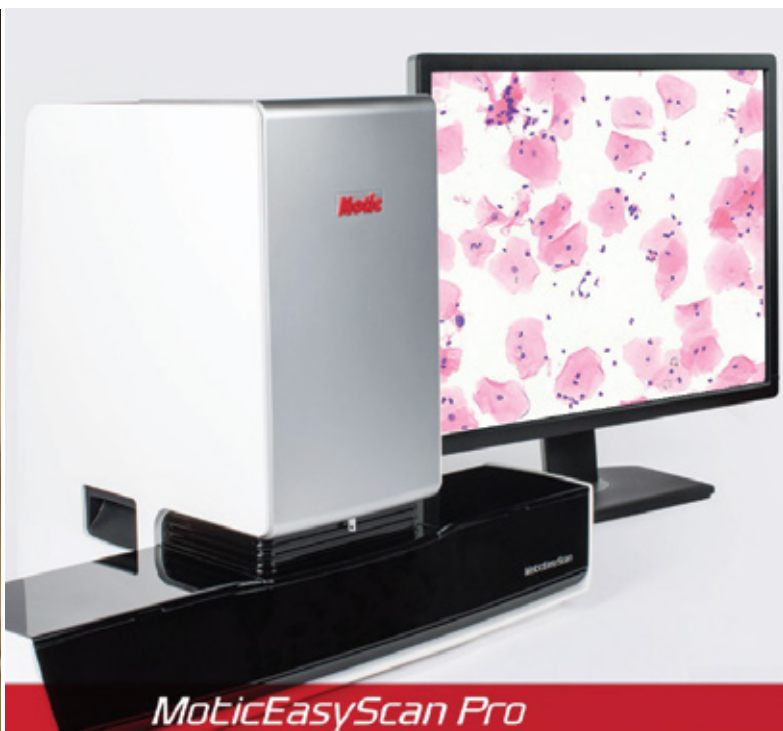Conformité Européenne (Health & Safety Regulator EEA)

China Food and Drug Administration (Health Regulator)

Central Drugs Standard Control Organization

(Indian Regulator for Diagnostic Devices)

Non-Invasive Sampling & AI-Powered DNA Analysis



Breakthrough in Oral Cancer Treatment

The tissue fluorescence visualization science that is the foundation of VELscope's technology is backed by over \$50 million in research funded by the NIH and other prestigious organizations. An impressive 92% of VELscope Vx using oral healthcare professionals say they would recommend it to colleague.

A number of papers have appeared in the literature to support that VELscope is an invaluable tool to help specialists in the management of oral lesions. The landmark paper, "Fluorescence visualization detection of field alterations in tumor margins of oral cancer patients" (Poh et al, 2006) laid the groundwork for the surgical margin claim for VELscope that was cleared by the FDA. In this paper, 20 primary cancers were assessed with a stepwise protocol that first included an assessment of the lesion under normal surgical lighting with the apparent clinical extent of the tumor was marked with a surgical pen. Then the VELscope was used to map out the area of abnormal fluorescence visualization loss (FVL) around the tumor. This almost invariably larger area was similarly marked with a surgical pen. Then the lesion was excised with a clear margin where the fluorescence had returned to normal or FVR (fluorescence visualization retention). To evaluate the performance of the fluorescence technique, multiple histological tissue samples were acquired from the excised specimens: from the clinically apparent tumor, the areas around the clinically apparent tumor which appeared normal but which demonstrated an abnormal loss of fluorescence (FVL), and finally the normal margins which looked normal both under white and with through the VELscope (FVR).

The results of this histological assessment were as follows:

- 122 biopsies were acquired in total – 20 from the tumors, 36 from the FVL margins and 66 from the FVR margins

- 32 out of 36 FVL biopsies showed histological changes:
- 7 squamous cell carcinoma
- 10 severe dysplasia
- 15 mild/moderate dysplasia
- 65 out of 66 FVR biopsies were normal
- 1 abnormal biopsy: mild/moderate dysplasia
- In the 10 tumors showing > 10mm FVL extension, 6 tumors showed severe dysplasia or cancer in biopsies taken > 10 mm from the clinical boundary.

In total, 19 out of 20 tumors had FVL boundaries extending beyond the clinically apparent lesion. Moreover, if a conventional 10mm clearance of the clinical tumor had been used, 50% of the tumors in this study would have had cancer or dysplasia at the clinical margin, 30% (6) showing severe dysplasia or CIS. These six tumors would have had a high chance of tumor recurrence because of inadequate tissue removal.

In 2007, a paper entitled "Direct fluorescence visualization of clinically occult high-risk oral premalignant disease using a simple hand-held device" was published in Head & Neck (Poh et al) that provided case studies with full color photographs of premalignant lesions that were essentially invisible to the naked eye but readily apparent using the VELscope. In addition to the above this work, this paper helped substantiate the indication cleared by the FDA that the VELscope can "enhance the visualization of oral mucosal abnormalities that may be or may lead to oral cancer and that may not be apparent or visible to the naked eye." Exciting new research has recently appeared in the literature describing a retrospective analysis comparing patients at the British Columbia Cancer Agency who had undergone surgical excision of cancerous lesions with and without the use of fluorescence visualization guidance using the VELscope.

Since it is well documented that that oral cancer recurs in a significant percentage of patients following oral cancer surgery, the key endpoint considered was the percentage of patients with high risk lesions at the treated site when examined at follow-up. The results were published recently in Cancer Prevention

Research (Poh et al) and tracked 60 oral cancer patients who were treated with surgical excision only during 2004-2008. Thirty-eight patients had VELscope-guided surgery (i.e., the surgical margin was 10 mm beyond the tumor edge defined by the VELscope exam), while 22 patients—the control group—did not have VELscope-guided surgery (i.e., the surgical margin was 10 mm beyond the tumor edge defined by the standard white-light exam). All 60 patients had a follow-up time of at least 12 months. The follow-up revealed that 7 of the 22 control group patients had experienced a recurrence of severe dysplasia or more serious tumors, while none of the patients who had VELscope-guided surgery experienced a recurrence of severe dysplasia or cancer.

This dataset is in fact a subset taken from of a larger group of patients who were treated at the British Columbia Cancer Agency from 2004 to 2008. This group included not just patients with cancer-ous lesions but with all “high-risk lesions” (HRLs) including severe dysplasia and carcinoma-in-situ. An analysis of this larger group is still unpublished but was presented as an abstract/poster at the University of British Columbia Dentistry Research Day 2009 on January 29th 2009. From 2004-2008, 163 patients at the British Columbia Cancer Agency with high-risk lesions (HRLs) had surgical excision with minimum 6-month follow-up:

1. 87 under FV guidance (FV Group)
2. 76 conventional surgery (Control Group)

The results were just as striking as the ones described above with only 2% of the FV Group presenting with severe dysplasia or worse compared to 41% for the control group

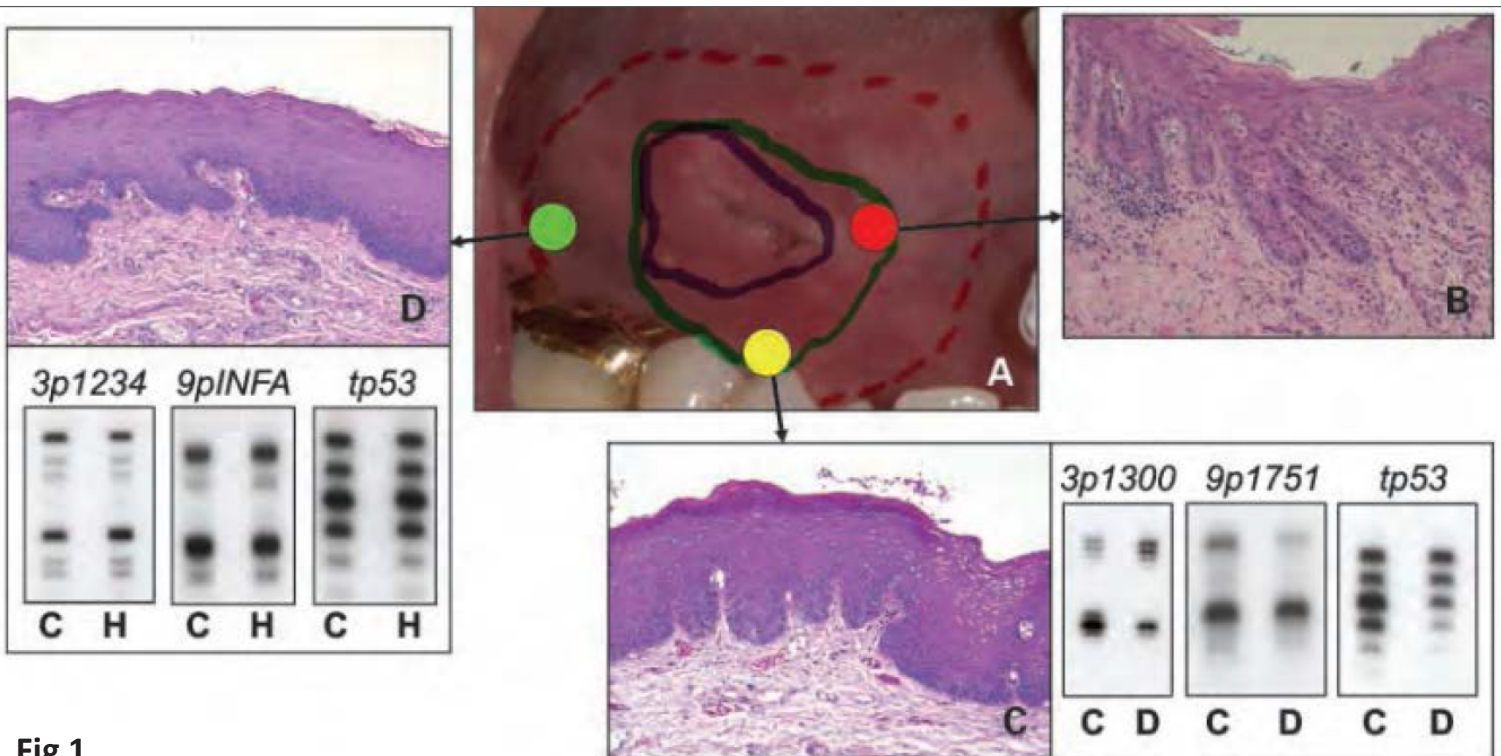


Fig 1

Presence of high-grade histology or molecular clones in FVL margins outside of clinically apparent tumor. A, mapping of surgical field showing three boundaries: clinically apparent tumor (blue), FVL boundary (green), and boundary of surgical specimen (red). B, photomicrograph of FVL margin (red circle) showing high-grade dysplasia. C, photomicrograph and LOH images of FVL margin (yellow circle) showing mild dysplasia with LOH at D3S1300, D91751, and tp53. D, photomicrograph and LOH images of FVR margin (green circle) showing no dysplasia and heterozygosity (no LOH) at D3S1234, D9INFA, and tp53. Magnification, $\times 100$.

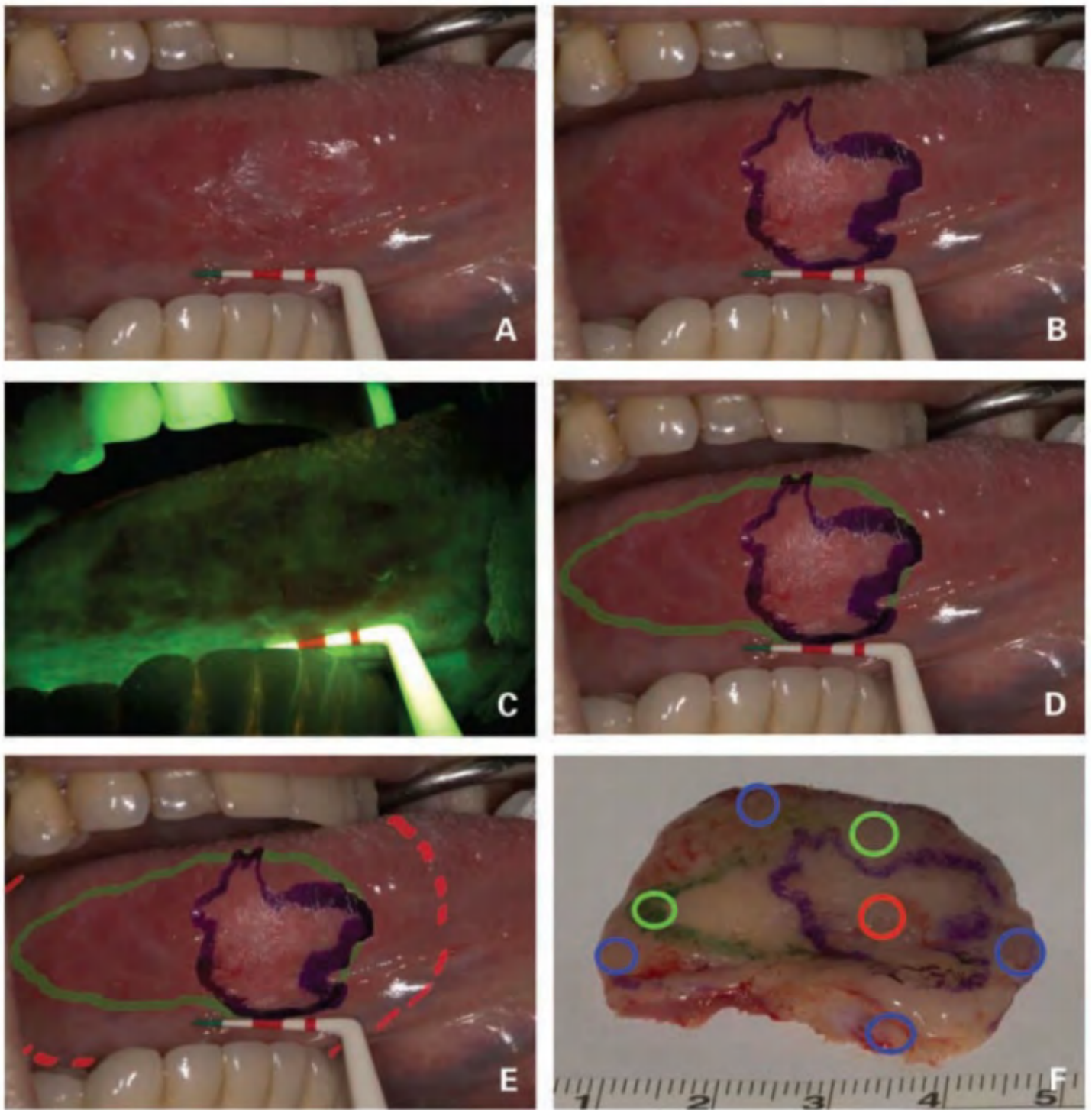


Fig 2

Stepwise protocol used for assessing surgical field. A, in the operating room, initial assessment under white light of an ill-defined SCC at right ventrolateral tongue; B, clinically apparent tumor outlined in blue; C, assessment of field using FV in the dark; D, FVL area outlined in green in the dark; E, boundary of surgical specimen (red); F, blocking of surgical specimen, showing location of punch biopsy sites from clinically visible tumor (red circle), from tissue showing FVL, placed directly abutting FVL boundary (green circle), and, from tissue showing FVR, placed directly abutting the boundary of surgical specimen (blue circle).

About VELscope Vx

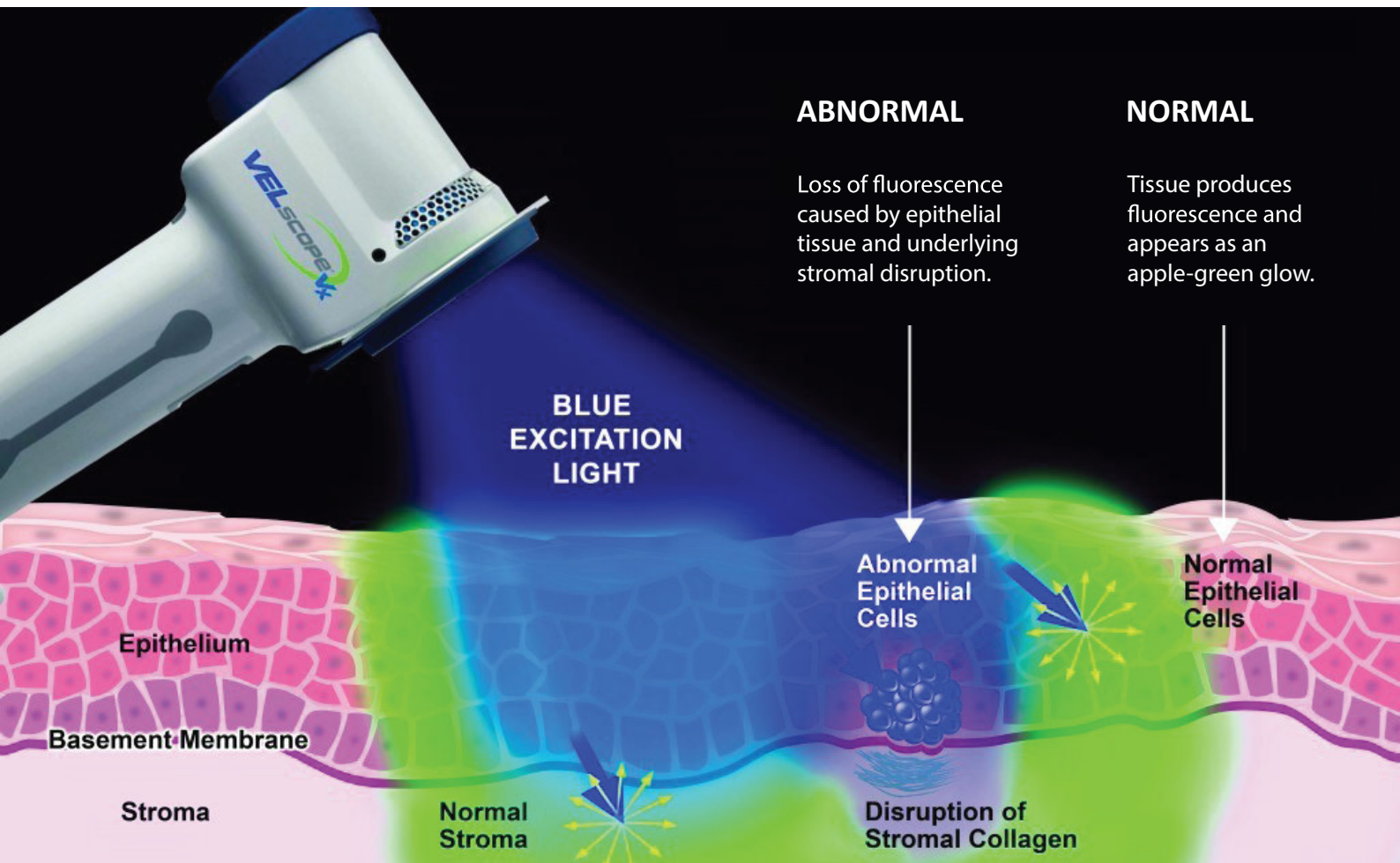
VELscope Vx Enhanced Oral Assessment System, which centers on a wireless, handheld scope that uses natural tissue fluorescence to enhance the way clinicians visualize oral mucosal abnormalities that might not be apparent or even visible to the naked eye.

Recognized by the World Health Organization in 2009 as a commercialized medical device that addresses global health concerns and is accessible to low and middle-income countries, the award-winning VELscope Vx is among the world's most widely used devices for the enhanced visualization of oral mucosal abnormalities.

Supported by clinical studies illustrating the efficacy of the VELscope's tissue fluorescence visualization, the device is used over 15,000 dental practitioners in 23 countries worldwide.

The VELscope Vx is used to help detect lesions that may not be visible under traditional white light examinations, including precancerous and cancerous growths. It is further used by surgeons to help identify diseased tissue around a clinically apparent lesion and thus aid in determining the appropriate margin for surgical excision to help surgeons ensure that all diseased tissue is successfully removed when excising cancerous lesions.

- **VELscope® Vx is recognized by World Health Organization (WHO)**
- **VELscope® Vx is the first technology approved by the USA FDA and Health Canada for early detection of cancerous and precancerous lesions, that might be invisible to the naked eye, and to help determine the appropriate surgical margin when excision is indicated.**
- **This technology was developed by British Columbia Cancer Agency and MD Anderson Cancer Center in Houston, backed by over \$50 million in research funded by NIH.**
- **The technology is backed by more clinical studies than any other device for tissue fluorescence visualization.**
- **More than 25 million VELscope Vx examinations have been performed by over 15,000 dental practitioners in 23 countries.**



1. Early Disease Discovery

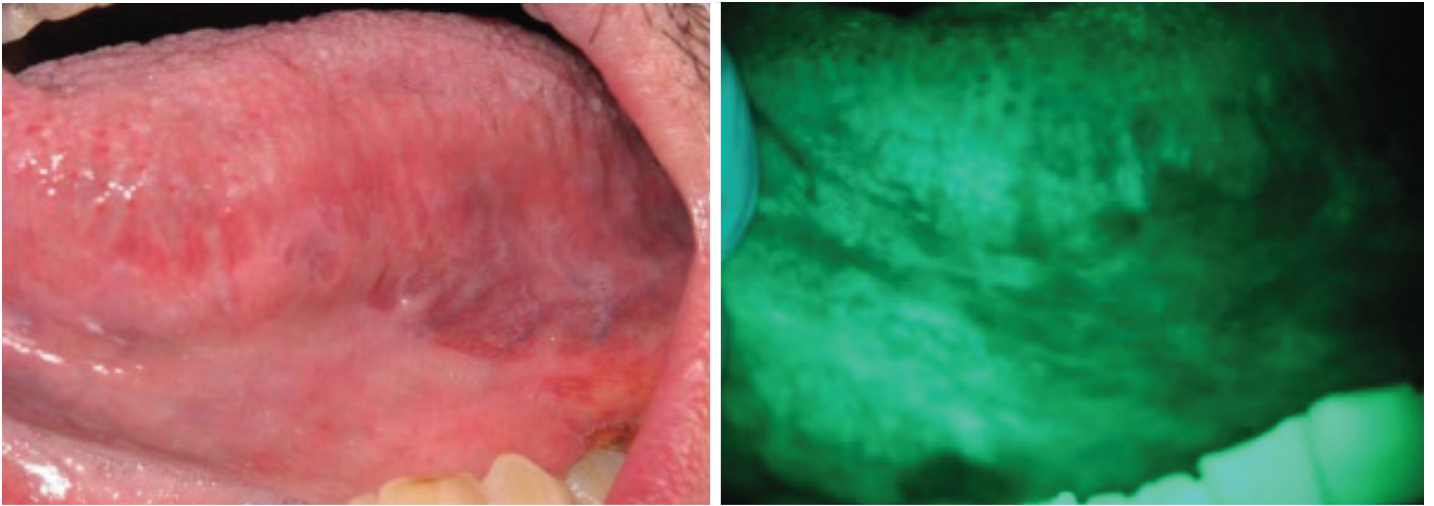


Figure 1. Dysplastic lesion demonstrating visual enhancement with VELscope compared to white light alone.

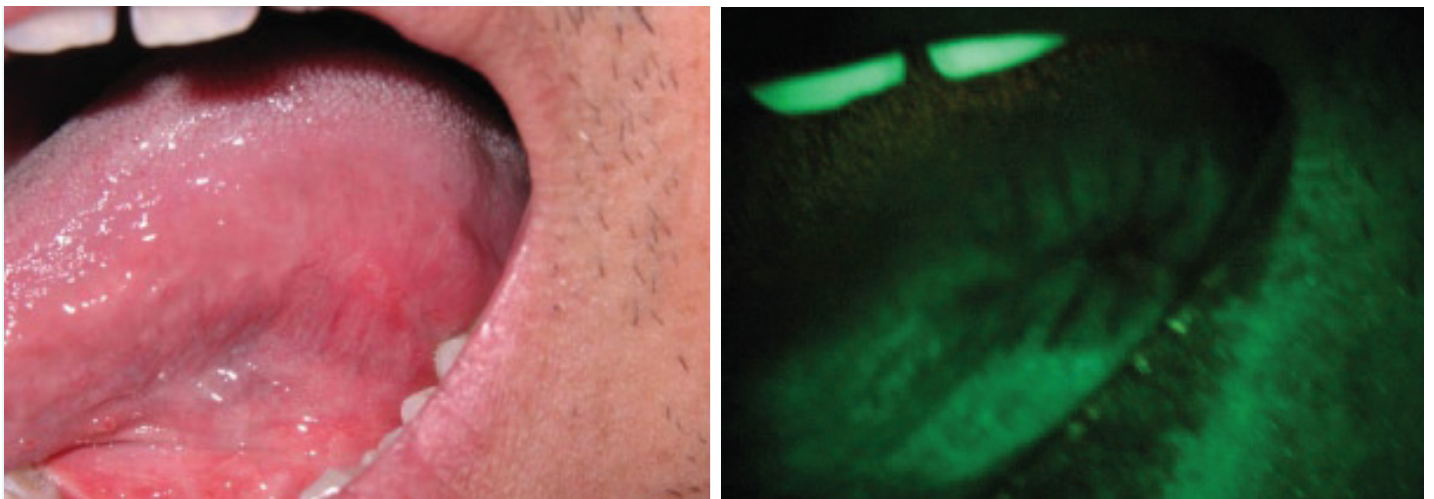


Figure 2. Another dysplastic lesion demonstrating visual enhancement with VELscope.

Figure 1 and Figure 2 are examples of dysplastic lesions whose visual appearance is markedly enhanced with the use of the VELscope system compared to white light alone. Upon referral from a GP using VELscope to a specialist in such cases, it is highly advantageous for the specialist to have a VELscope system available so as to properly understand the reason for the referral and the particular areas that might have been of concern for the GP.

2. DNA Ploidy Sampling Site/ Biopsy Site

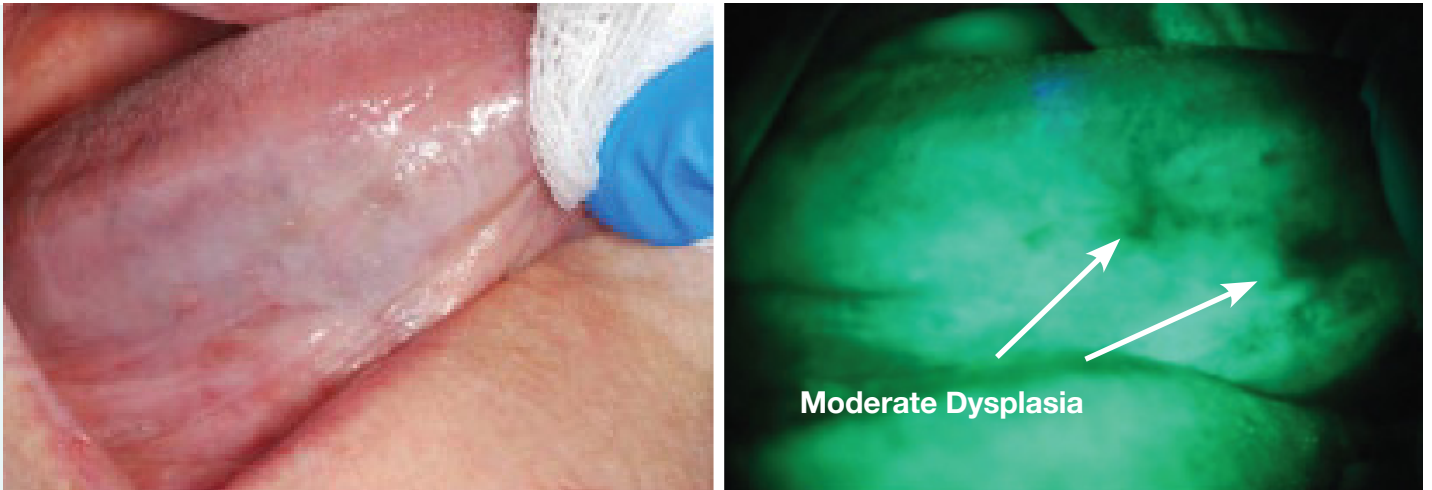


Figure 3. Broad area of leukoplakia under white light – fluorescence suggests particular areas of concern.

Figure 3 suggests the usefulness of fluorescence visualization in to help in identifying appropriate sites for biopsy. In this case, what presents as a broad area of leukoplakia under white light, shows two distinct dark areas under fluorescence using VELscope. Both of these areas were found to contain moderate dysplasia upon biopsy.

3. Surgical Margins

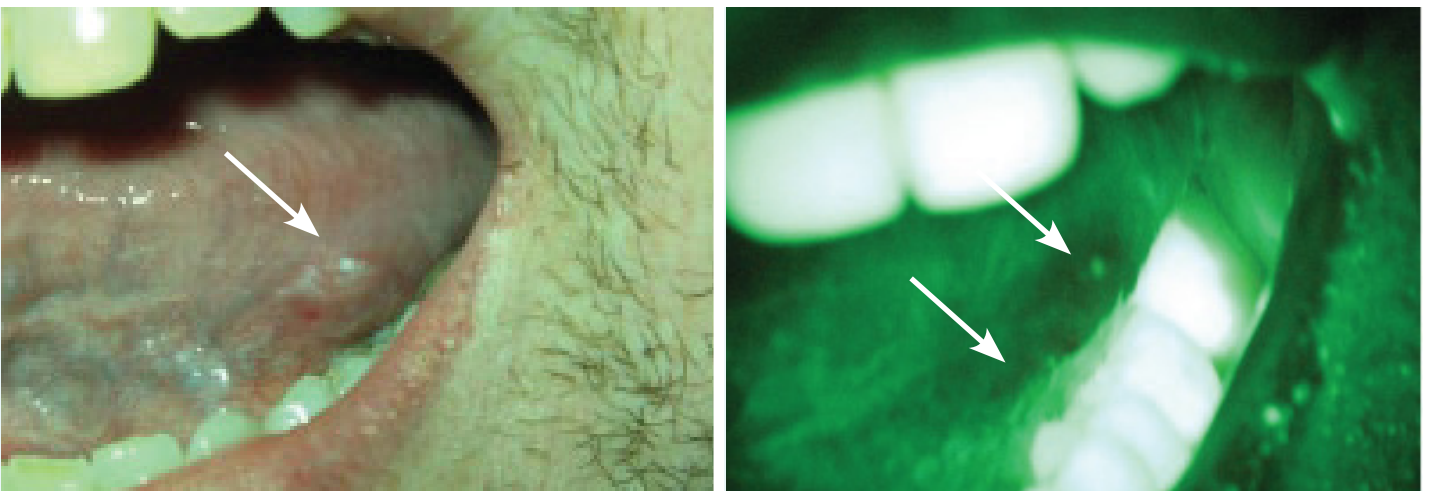


Figure 4. Dysplastic lesion showing a loss of fluorescence suggesting a larger area for surgical excision.

Figure 4 shows an example of a dysplastic lesion which based on its suspicious appearance under white light alone was appropriately referred for biopsy. The loss of fluorescence through VELscope confirms the suspicious nature of the lesion but also shows a distinct abnormal lack of fluorescence away from, and anterior to, the clinically obvious lesion. Cytology and biopsy confirmed the presence of dysplasia in this area as well. The extension of mucosal change anterior to the clinically obvious area under white light suggests an area for surgical excision larger than what otherwise might have been considered. In particular, note the asymmetrical pattern of loss of fluorescence around the area obvious area under white light. This is a characteristic that was noted in the surgical margin research papers discussed above.

We encourage you to explore the information provided on the VELscope website to learn more about how the VELscope system can support your efforts.

4. Full Scope of Mucosal Involvement

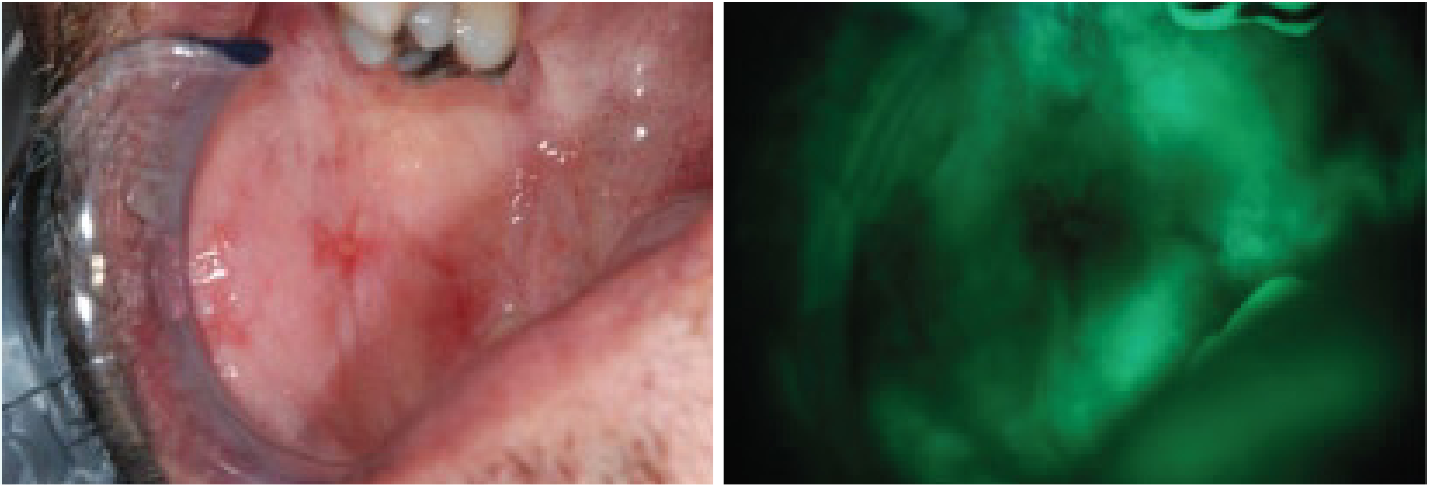


Figure 5. Erosive Lichen Planus under white light and through the VELscope.

Figure 5 is an example of erosive lichen planus demonstrating the ability of fluorescence visualization using VELscope to provide an enhanced appreciation for the full extent of mucosal involvement of a particular lesion or lesions. While useful for relatively common conditions such as lichen planus it can be critical for precancerous and cancerous lesions. Such an example is provided next in Figure 5.

5. Lesion Risk Assessment

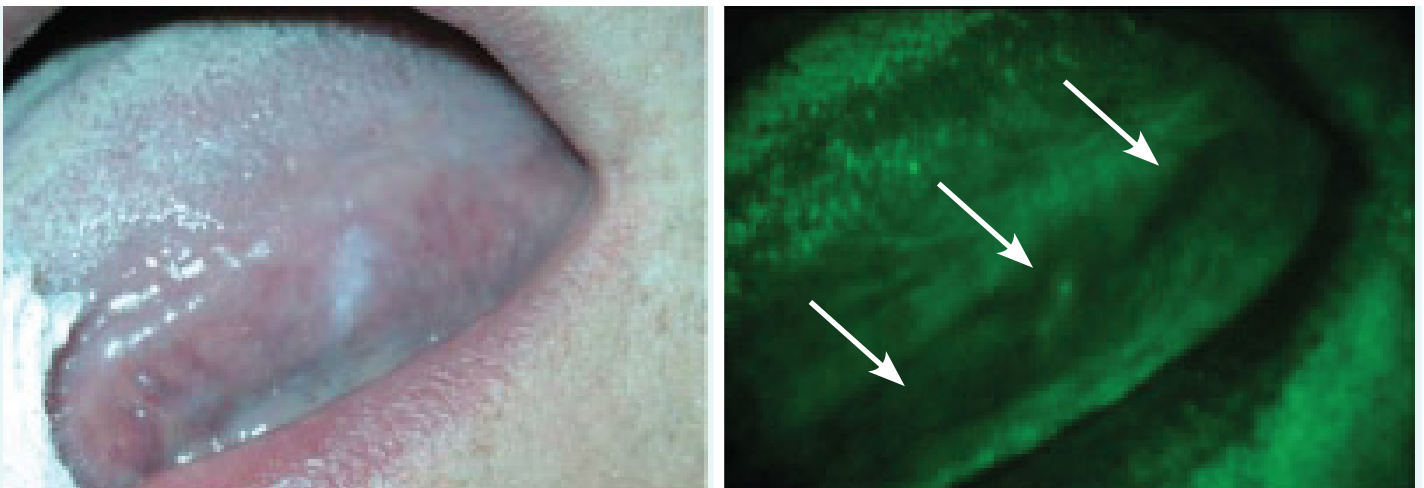


Figure 6. VELscope can help raise suspicion about seemingly innocuous lesions.

Figure 5 is a lesion that when initially assessed without the use of VELscope was thought likely to be the result of trauma. However, the presentation under VELscope does not fit this picture. Not only is the white, non-inflamed-looking area under white light dark through the VELscope but there is an

6. Satellite Lesions

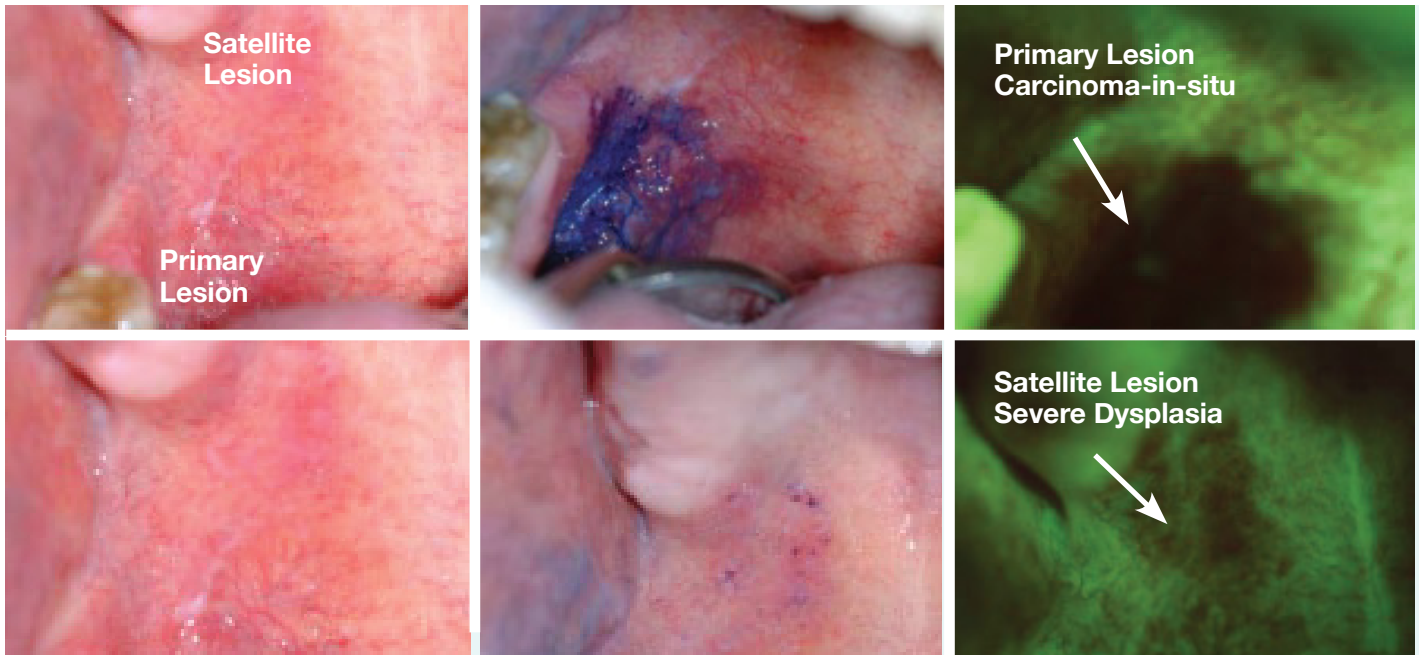


Figure 7. A satellite lesion found to be severe dysplasia whose discovery was facilitated through the use of VELscope.

Figure 7 is a classic example, not only of a clinically occult lesion, carcinoma-in-situ, that presents with a dramatic loss of fluorescence through the VELscope, but also of how the VELscope can facilitate discovery of satellite lesions that might easily be overlooked. In this case, there is lesion containing severe dysplasia quite close to but distinct from the primary lesion. Note that for the primary lesion, the Toluidine blue positive area is distinctly smaller than the area demonstrating loss of fluorescence. For the satellite lesion, very little Toluidine blue stain is retained despite the distinct loss of fluorescence and presence of severe dysplasia.

References

[1] **N. Denaro et al., 2016**

[2] **SB Thavarool et al., 2019**

[3] **Vikram, et al., 1984**

[4] **Poh et al., 2016**

[5] **The Journal of the American Medical Association**

Rana et al, 2012

“5 of the 6 dysplastic lesions were discovered using the VELscope examination but missed by the prior white light examination.

Zhang et al, 2007

“FVL was significantly correlated with the severity of histology, present in 24% non-dysplastic, 73% low-grade, 94% high-grade lesions and 96% cancers. These data supports the use of the VELscope as an adjunct tool to identify high-risk oral lesions.”

Poh et al 2006

“In total, 19 out of 20 tumors had FVL boundaries extending beyond the clinically apparent lesion. Moreover, if a conventional 10mm clearance of the clinical tumor had been used, 50% of the tumors in this study would have had cancer or dysplasia at the clinical margin, 30% (6) showing severe dysplasia or CIS. These six tumors would have had a high chance of tumor recurrence because of inadequate tissue removal.”

Poh et al 2009

After a minimum of 12 months follow-up, 7 of the 28 (25%) patients who underwent non-fluorescence guided surgery experienced severe dysplasia or worse at the treated site. None (0%) of the VELscope-guided surgery patients had severe dysplasia at the treated site.

Poh et al 2016

“Among the 156 patients with squamous cell carcinoma, in 92 patients in the FV group showed significant reduction in the 3-year local recurrence rate, from 40.6% to 6.5%
Among the 90 patients with high-grade lesions, the 62 patients in the FV group showed a reduction in local recurrence rate from 11 of 28 patients (39.3%) to 5 of 62 patients (8.1%).”

Remmerbach et al. 2003

“DNA-ICM + PAP sensitivity to 98.2%, specificity to 100%, PPV 100% NPV 99.5%

The advantages of brush biopsies: brushings of all visible oral lesions, easily practicable, cheap, noninvasive, largely painless, safe and accurate screening method for detection of oral precancerous lesions (dysplasias), carcinomas in situ or invasive squamous cell carcinoma in all stages. DNA-image cytometry is a very sensitive, highly specific and objective adjuvant tool for the earliest identification of neoplastic epithelial cells in oral smears.”

Böcking A. et al. 2013

The cytometric detection of DNA-aneuploidy in exfoliated suspicious dysplastic oral cells qualifies these as malignant, up to 2 years earlier than cytology or histology alone. Applying DNA-aneuploidy as a marker for prospective malignancy on identical slides, 29.4% of oral cancers that clinically appeared as leukoplakias or erythroplakias were detected in stages Tis or T1.

D.Maraki et al. 2004

PAP + DNA-ICM sensitivity 100% and specificity 97.4% for evaluation of oral leukoplakias and erythroplakias. DNA-ICM PPV 100%, NPV 98.1%

Guillaud et al. 2006

Showed DNA-ICM superiority over conventional cytology and HPV testing.

Huff et al 2009

“The authors conclude that the addition of FV to the standard oral cancer screening protocol increased the sensitivity in detection of oral potentially premalignant lesions, thus supporting the usefulness of the VELscope system in a private practice setting for detecting such lesions.”

Truelove et al. 2011

“620-patient study at the University of Washington demonstrated that the addition of VELscope to routine clinical examinations resulted in the detection of a number of mucosal abnormalities not detected by the conventional exam. VELscope provide general practitioners with a powerful tool to aid in the discovery of most types of oral lesions (not only pre-cancer and cancer), such as viral, fungal and bacterial infections; inflammation from a variety of causes (including lichen planus and other lichenoid reactions); squamous papillomas, salivary gland tumours, etc.”

NO: 123600

Barcode: 10180047

Name: Sample

Gender: Male

Age: 72


Phone: 0000000000

Ref Hosp: Clinic

Ref Dr:

Specimen: Oral brushing

Cell Gallery



Group	Count
Leucocyte	7403
Normal	2970
Cycling or Neoplastic	43
Abnormal Cells	5
	3,018

DNA Diagnosis:

3 or More Cells of Abnormal DNA Ploidy

Recommendation:

Biopsy

Dr. Bhanu Chugh
Oral Pathologist

Remarks

Print Date: 18/4/2018

- 1.) DNA Index (DI) near 1 is normal, between 1.2 and 2.5 is usually normal, and ≥ 2.5 is abnormal ploidy.
- 2.) QC parameters: CV:4.88, IOD:103.79, ET:10
- 3.) Print Date: 18/4/2018 3. Please Call or WhatsApp +91.9990444646/9990494947 or Email report@mydnalabs.com if you have any questions.,

We encourage you to explore the information provided on www.velscan.com website to learn more about how the VELscope system can support your efforts.

Your expertise and the VELscope's technology can form a powerful combination that will truly make earlier detection, diagnosis and successful treatment of oral disease a reality.

